

Re: John Smith, UR No: 00000 DOB: 20/12/1972 Age: 42 years 3 months 8 days 1 Children Court BAREWELL QLD 40000 Medicare no. 40000000	Dr S SURGEON (0000000A) No More Children Clinic, 1 Queensland Road CITY QLD 4000 Tel. 07 0000 0000 Copy to: Dr. G Practitioner Fax: 07 0000 0001
Lab Number: 15B-00000	Referral date: 9/03/2015 Released: Saturday, 10 March 2015

HISTOPATHOLOGY REPORT:

CLINICAL NOTES:

VAS histology – bilateral vasectomy specimen

MACROSCOPY:

1. Left vas: The specimen consists of a pale cylindrical portion of tissue measuring 22mm in length and 3mm in diameter. Inked blue, 1 R/S, block 1.
2. Right vas: The specimen consists of a pale cylindrical portion of tissue measuring 42mm in length and 3mm in diameter. Inked black, 1R/S, block 2. (RT/at)

MICROSCOPY:

1. The sections of the vas deferens show **FULL TRANSECTIONS**. There is no evidence of inflammation or malignancy.
2. The sections of the vas deferens show **FULL TRANSECTIONS**. There is no evidence of inflammation or malignancy.

CONCLUSION:

1 & 2. LEFT AND RIGHT VAS, BILATERAL VASECTOMY:
- 2 x FULL TRANSECTIONS OF LUMEN

REPORTED BY:

Dr. InfinityPATH Consultant Specialist Histopathologist

MBBS (Hons) FRCPA

Mobile: 0451 000 000

Email: infinity.path@infinitypath.com.au

NATA Accreditation Number 19215

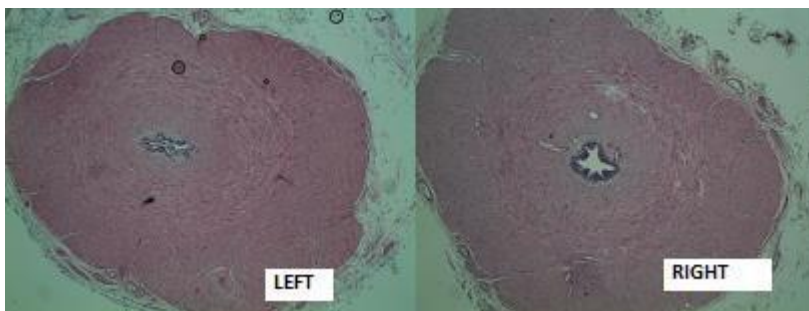


Figure 1 BILATERAL VASECTOMY