

**HISTOPATHOLOGY REPORT: **EXAMPLE REPORT****

**CLINICAL NOTES:**

Diarrhea and recent weight loss; random biopsy, colonoscopy

**MACROSCOPY:**

Labelled random colon biopsy: Two pieces of tan tissue measuring 6mm in greatest dimension. All in. 1 block. (SL/dh)

**MICROSCOPY:**

The sections of colonic mucosa show **SIGNET RING ADENOCARCINOMA**. There is diffuse infiltrate of malignant signet cell within the lamina propria. There is no ulceration. (See **Figure 1 Below**)

**CONCLUSION:**

**RANDOM COLON, BIOPSY:**

- **SIGNET RING ADENOCARCINOMA**

- **Result phoned to referring Doctor – Thursday 17/4/2014 10:45am.**

**REPORTED BY:**

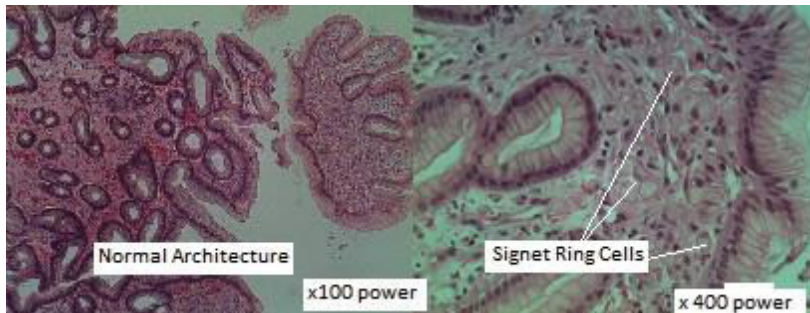
Dr Shahin Sharifi

MD MRCP (Part 2) FRCPA

Mobile: 0451 782 722

Shahin.sharifi@infinitypath.com.au

NATA Accreditation Number 19215



**Figure 1 Random Colon - Signet Ring Adenocarcinoma**

Patient Education : <http://emedicine.medscape.com/article/277496-overview>

Colonoscopy Patient Video: <https://youtu.be/0EWQHiv6Msc>

Colonoscopy Follow-up Recommendation: <http://loganendoscopy.com.au/index.php>

Colorectal Specialist Follow-up: <http://www.brisbanecolorectal.com.au/Welcome.html>