

HISTOPATHOLOGY REPORT: EXAMPLE REPORT

CLINICAL NOTES:

RIGHT SCAPULA, excision biopsy confirmed
- NODULAR BASAL CELL CARCINOMA (BCC)

MACROSCOPY:

Right scapula: The specimen consists of an ellipse of skin measuring 40x12x7mm bearing a central pale tan patch measuring 14x10mm. 2TS, block A. 2TS, block B. 2 blocks. (RT/ba)

MICROSCOPY:

The sections of skin excision show NODULAR **BASAL CELL CARCINOMA**. The carcinoma extends into the upper reticular dermis. There is no perineural invasion. There are surgical biopsy changes present. **See Figure 1**. Clearance from carcinoma:

- Peripheral: 1.8mm
- Deep: 2mm

CONCLUSION:

RIGHT SCAPULA, SKIN EXCISION:

- NODULAR **BASAL CELL CARCINOMA** (BCC)
- 14mm
- EXCISION APPEARS COMPLETE

Educational Hyperlink <http://www.infinitypath.com.au/doctor-education/basal-cell-carcinoma-bcc/>

REPORTED BY:

Dr. InfinityPATH Consultant Specialist Histopathologist
MBBS (Hons) FRCPA
Mobile: 0451 000 000
Email: infinity.path@infinitypath.com.au
NATA Accreditation Number 19215
See the difference, Feel the difference, Be part of our journey

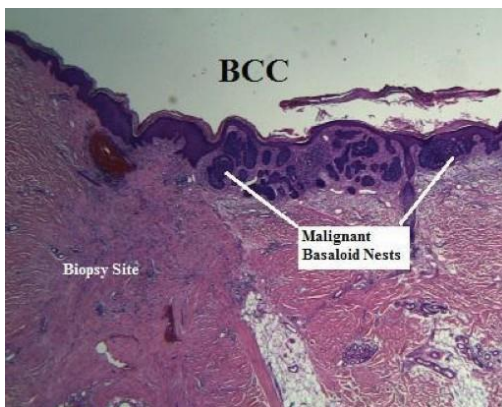


Figure 1 Right scapula Histology