

InfinityPATH

Unit 6, 3245 Logan Rd., Underwood, QLD 4119

Brisbane : Tel (07) 3123 8888 Fax (07) 3123 8889
Gold Coast : Tel (07) 5609 7188 Fax (07) 5609 7288
Sunshine Coast: Tel (07) 5329 7888 Fax (07) 5329 7889

Re: A Patient UR No: 25000 DOB: 06/07/1961 Age: 52 years 9 months 11 days Good Street Surburb QLD 4000 Medicare no. 411111111/1	Dr A Gastroenterologist Private Hospital 1 Health Street HEALTH 4000 QLD Tel. 07 0000 0000 Copy to: Dr A Gastroenterologist Level 3 1 Subspecialist Street, SURBURB 4000 Copy to: Dr GP Fax: 07 1111 1111
Lab Number: 14B-7201	Referral date: 16/04/2014 Released: Thursday, 17 April 2014

HISTOPATHOLOGY REPORT:

CLINICAL NOTES:

Polyp Right Colon dx Re: dysplasia

MACROSCOPY:

Labelled colon biopsy: Two pieces of tan tissue measuring 6mm in greatest dimension. All in. 1 block. (SL/dh)

MICROSCOPY:

The sections of colonic mucosa show **SESSILE SERRATED ADENOMA**. There is serrated architectural with low grade dysplasia There is no evidence of high grade dysplasia, invasion or malignancy. (See Figure 1 Below)

CONCLUSION:

RIGHT COLON, BIOPSY:

- **SESSILE SERRATED ADENOMA**

REPORTED BY:

Dr. Glenn Francis Specialist Pathologist
MBBS (Honours) (UQ) FRCPA

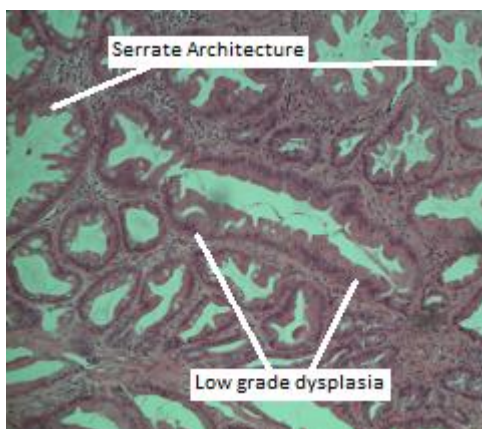


Figure 1 Right Colon Biopsy - Sessile Serrate Adenoma