

**HISTOPATHOLOGY REPORT: EXAMPLE REPORT**

**CLINICAL NOTES:**

Bx histopath antrum  
Clo. See figure below.

**MACROSCOPY:**

Antral Bx: The specimen consists of one tan portion of tissue measuring 4mm in largest dimension. All in, 1 Block.  
An AB-PAS and HP are ordered for this specimen. A CLO test is also received. (SC/sa)

**MICROSCOPY:**

The sections show antral type gastric mucosal fragment. The fovea-glandular architecture is preserved. There is a chronic inflammatory cell infiltrate in the lamina propria consisting of lymphocytes and plasma cells. There is no active inflammation. There are no Helicobacter-like organisms seen on routine or on immunohistochemical stains. There is no intestinal metaplasia seen. There is no evidence of dysplasia or malignancy.

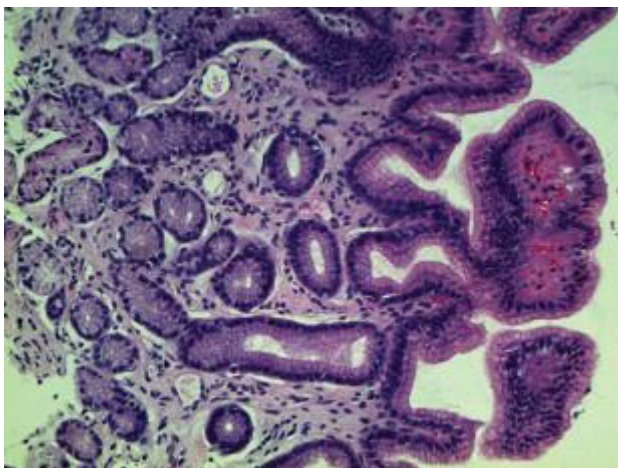
**CONCLUSION:**

**ANTRAL BIOPSY:**

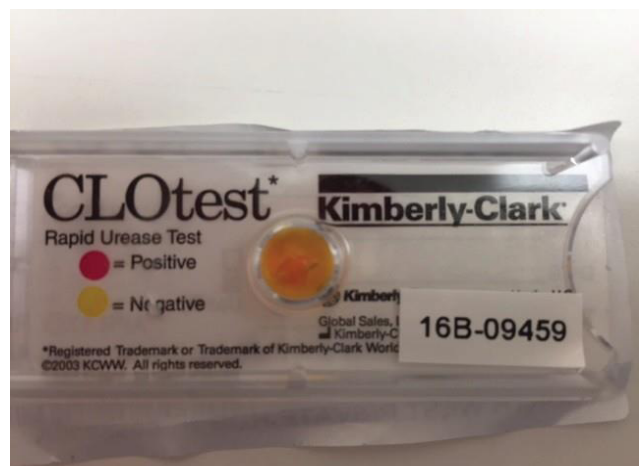**- MILD SUPERFICIAL CHRONIC GASTRITIS**

**REPORTED BY:**

Dr. Kosala Liyanaarachchi Consultant Specialist Histopathologist  
MBBS (University of Colombo), Diploma in Pathology, MD (Histopathology), FRCPA  
Mobile: 0416 520 588  
NATA Accreditation Number 19215



**Figure 1**  
**MILD SUPERFICIAL CHRONIC GASTRITIS**



**Figure CLO TEST -NEGATIVE**