

**HISTOPATHOLOGY REPORT: **EXAMPLE REPORT****

**CLINICAL NOTES:**

Gall Bladder  
Acute cholecystitis

**MACROSCOPY:**

Gallbladder: The specimen consists of an opened gallbladder measuring 70mm in length and 30mm in maximum fundal diameter. A possible cystic duct lymph node is present measuring 6mm in maximum dimension. There are no calculi in the lumen or specimen container. The serosa is unremarkable. The gallbladder wall thickness ranges between 2 and 5mm. The mucosa shows patchy ulceration. No focal lesions are seen. Representative sections taken through the duct and node, Block A. Representative sections from the body and fundus, Blocks B and C. 3 blocks. (SC/sa)

**MICROSCOPY:**

The sections of cholecystectomy specimen show **CHRONIC CHOLECYSTITIS**. There is chronic inflammation and muscle hypertrophy. There is cholestrolosis. There is a reactive lymph node. There is no evidence of intestinal metaplasia, dysplasia or malignancy. (See Figure 1 Below)

**CONCLUSION:**

GALL BLADDER, CHOLECYSTECTOMY:

- **CHRONIC CHOLECYSTITIS.**
- **NO EVIDENCE OF MALIGNANCY.**

**REPORTED BY:**

Dr. Kosala Liyanaarachchi Consultant Specialist Histopathologist  
MBBS (University of Colombo), Diploma in Pathology, MD (Histopathology), FRCPA  
Mobile: 0416 520 588  
NATA Accreditation Number 19215

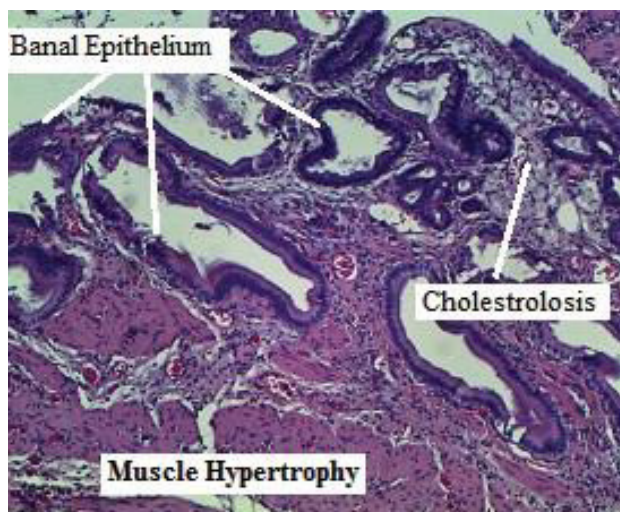


Figure 1 CHRONIC CHOLECYSTITIS